

# Large Primary Scrotal Lipoma in a Young Nigerian: A Case Report with Review of Literature

I.A.<sup>1</sup>Nwajei, N<sup>1</sup> Kogha, <sup>1</sup>R.O. Agboge, <sup>2</sup>J.C. Onyemesili, <sup>3</sup>B.E. Anyanwu, <sup>4</sup>O.J. Uchendu

1. Department of Radiology, Delta State University Teaching Hospital, P.M.B. 07. Oghara, Nigeria

2. Department of Radiology, Central Hospital Warri, Nigeria.

3. Department of Family Medicine, Delta State University Teaching Hospital, P.M.B. 07. Oghara, Nigeria

4. Department of Pathology, Delta State University Teaching Hospital, P.M.B. 07. Oghara, Nigeria

### Abstract

**Background:** Primary scrotal lipoma is a very rare clinical entity where tumour of mature adipocytes arise from the subcutaneous tissue of scrotal sac. Accurate clinical diagnosis is important to exclude possible differential diagnosis.

**Materials and Methods:** Case Report with Review of Literature

**Results:** We report a case of bilateral primary lipoma in a 21 year old Nigerian which initially posed a diagnostic dilemma due to its similarity with the testes, both in size, shape and appearance on ultrasound scan. Diagnosis was then made with the aid of Magnetic resonance imaging and the patient was managed with surgical excision and biopsy with no resultant post op complication. It is therefore recommended that for proper evaluation of patients with scrotal masses, radiological imaging modalities as well as histology are useful in aiding diagnosis.

**Keywords:** Scrotal Lipoma, ultrasound scan, Magnetic resonance imaging

### Introduction

Lipomas are benign tumours of mature adipocytes. They are the most common mesenchymal tumours and can occur in any part of the body. Primary scrotal lipoma is however a very rare clinical entity where tumour of mature adipocytes arise from the subcutaneous tissue of scrotal sac. Accurate clinical diagnosis is important to exclude possible differential diagnosis such as inguinal hernia, polyorchidism or even malignancies. Here, we report a case of large primary testicular lipoma in a Niger-Delta male, and provide a literature review of comparable cases.

### Case Presentation

A 21- year old male, presented to our center with complaint of scrotal swelling. The swelling are in both sides, over a duration of 5 years. During these years, it has been painless and has consistently increased in size until it was of concern to him.

Physical examination revealed multiple, irreducible, non-tender, rubbery masses at both sides of the scrotum, measuring 6.5 x 5.0cm and 7.0 x 6.5cm on the right and left scrotal sacs respectively. The masses are not attached to the testicles and do not trans-illuminate. There are no associated scrotal ulceration or edema. There is no family history of similar swelling and also no family history of cancer. We made an assessment of scrotal lipoma to rule out polyorchidism.

Full blood count, electrolyte and urea and urinalysis were normal. Ultra sound scan revealed a hyperechogenic solid mass, separated from both testicles (Figure II). Magnetic resonance imaging showed two (7.00 x 3.11 x 4.83cm) and (6.67 x 4.49 x 4.62cm), multilobulated isointense mass on T1 and T2 sequences which were suppressed on STIR sequence (Figure III). Both testicles were unremarkable.

Following a diagnosis of a tumour, a decision for surgical excision was made. During surgery, a midline, inferior scrotal incision was made. A well-encapsulated mass was enucleated from the scrotal wall without opening the tunica vaginalis (Figure IV). The specimen was immediately stored in 10% buffered formal-saline solution and submitted for histological evaluation. Histological sections consisted lobules of mature

### Correspondence to:

**Dr. Nwajei Ifeanyichukwu Anita**

Department of Radiology,

Delta State University Teaching Hospital,  
P.M.B. 07. Oghara, Nigeria.

Email: [inwajei@delsu.edu.ng](mailto:inwajei@delsu.edu.ng)

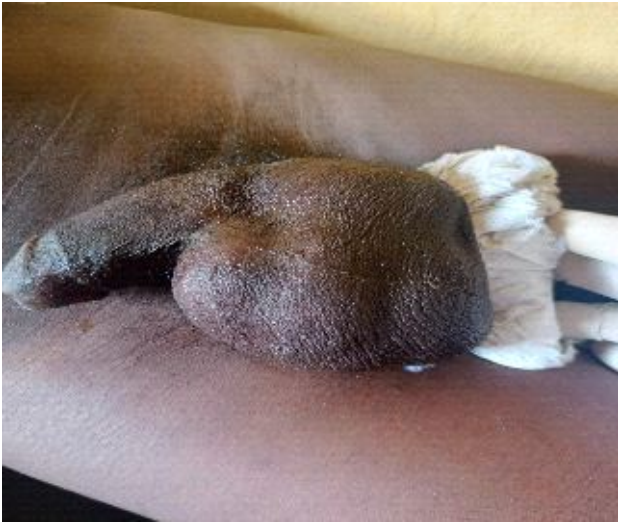

Figure I showing four scrotal masses (I,ii,iii,iv).

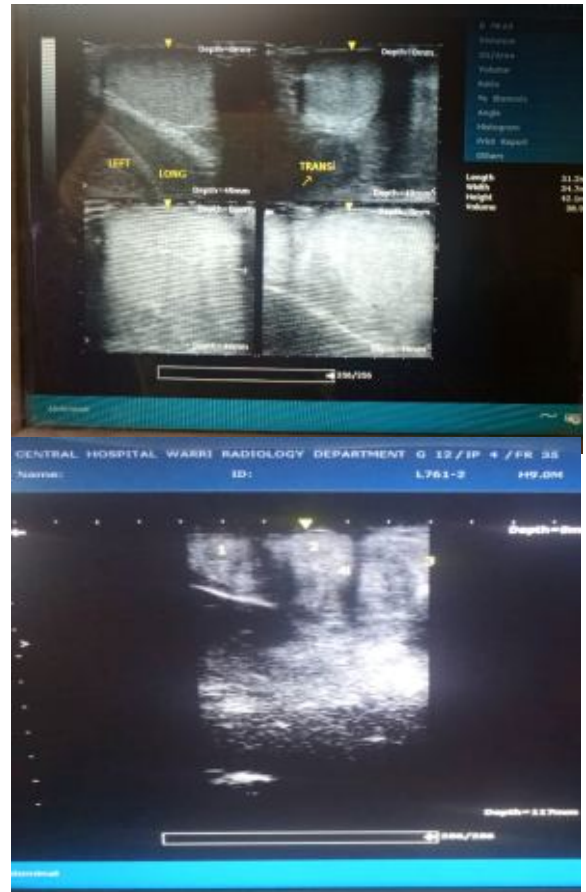

Figure II. Ultrasound scan of the scrotum showing homogenous isoechoic masses in the scrotal sac.

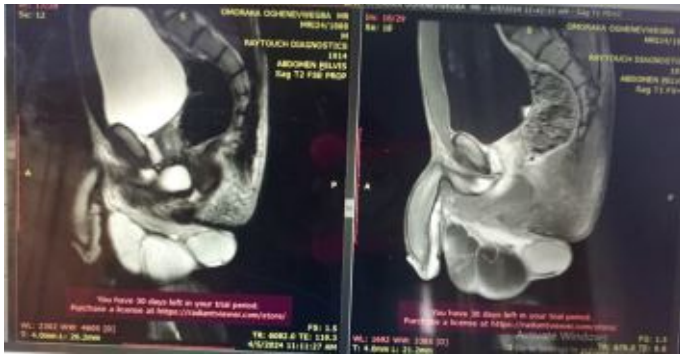

Figure III. Sagittal T2 and STIR MRI of the scrotum showing fat suppression of 2 scrotal masses.

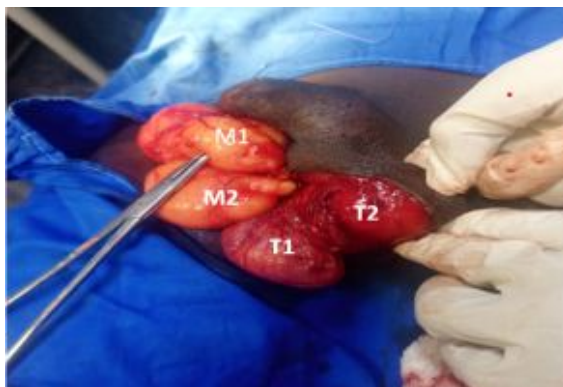


Figure IVa. Intra-operative Picture of the scrotum showing excised multiple scrotal lipomas. (M1&M2Scrotal Masses. T1&T2- Testes.)



Figure IVb showing multiple lobulated, well encapsulated mass.

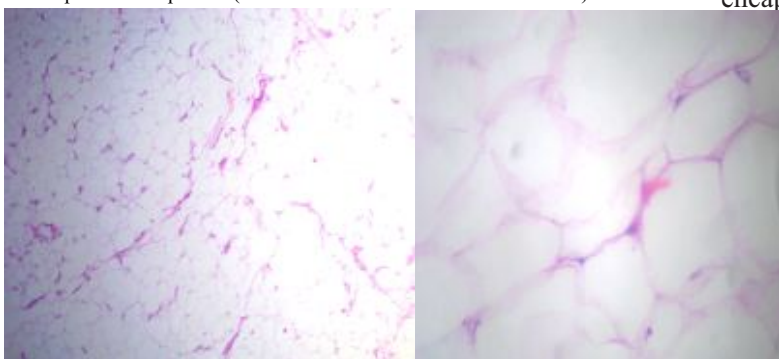


Fig Va (x4) and Vb (x10). Histology showing lobules of mature adipocytes separated by collagen.

adipocytes, separated by thin collagen with no evidence of cytological atypia (Figure V). The diagnosis of primary scrotal lipoma was consequently made. The post-operative condition was excellent and patient has been followed up for 6 months without any complication.

#### Discussion

Scrotal lipomas are benign mesenchymal tumours of the scrotum. Earlier researchers

have classified them into three groups based on their origin. Most have been said to arise from the spermatic cord, the adipocytes of the spermatic cord, or the scrotal wall.<sup>1</sup> Another classification is paratesticular and extratesticular.<sup>2</sup>

Based on this classification, our index case is identified as primary scrotal lipoma having its origin from the scrotal wall. While primary scrotal lipomas are found among boys and young men, other scrotal lipomas occur in men between the ages 40-60 years. This is in agreement with the age of the patient being reported.

This was similar to the study by Anwar et al, with both cases occurring in the 3<sup>rd</sup> decade of life.

Lipoma of the scrotum are extremely rare<sup>3</sup> and studies have shown that it occurs more commonly in the 5-6<sup>th</sup> decade of life<sup>4</sup>. But it has been seen to occur as early as in a 1 month old infant.

The clinical presentation of scrotal lipoma depends, to a large extent, on the size of the mass, weight and the pressure caused by the increased size, on the surrounding structures. That of our index case was simply complaints of painless scrotal masses which felt like multiple testes (polyorchidism). Physical examination revealed multiple, irreducible, non-tender, rubbery masses at both sides of the scrotum, which did not trans illuminate. Cases of painful masses may arise because of compression of peripheral nerves, as in the case of giant lipoma.<sup>2</sup> scrotal tumors are also associated with difficulty in walking or coitus.

Other causes of scrotal swelling such as hydrocele, varicocele, scrotal hernia, lymphedema and rarely filarial infections, that may cause scrotal swelling are to be avoided to avoid misdiagnosis. Other causes may be primary or metastatic testicular masses. The differential diagnosis of a scrotal lipoma varies ranging from scrotal spermatic cord lesions to testicular, epididymis, and other solid and cystic masses.

Primary scrotal lipoma can pose a diagnostic dilemma as has been reported in various studies

Radiological investigations have been found useful in optimizing the diagnosis of scrotal lipoma. The main diagnostic tool for scrotal masses, is usually the Ultrasound scan, which is cheap, readily available in low- resource settings, and usually the first modality of choice to evaluate scrotal and para-testicular masses, as it helps in the localization of the lesion and assessment of its consistency whether it is cystic or solid as well as exclude other differentials.<sup>2,6,7</sup> However, ultrasound scan is operator-dependent, has low specificity in differentiating benign tumors from malignant, and it

does not usually allow definitive characterization of these masses.<sup>8</sup> In this index case, both masses presented as non-specific painless scrotal mass, hyperechoic with uniform smooth margins. (Fig 2) On ultrasound, the scrotal masses, one in each sac, were homogeneously hyperechoic, with well-defined smooth margins and located in the medial aspect of both scrotal sacs, and could not be differentiated from the normal closely adjacent testes which gave the appearance of paired testicles bilaterally. Due to this similarity in appearance with the testes, the initial diagnosis of supernumerary testis was made and this informed the decision for further imaging, in this case, MRI, to further characterize the scrotal masses.

Magnetic resonance imaging, (MRI) an important imaging modality with excellent soft tissue resolution, is very useful in differentiating scrotal masses from the testes by evaluating the tumor location, morphologic features, and further tissue characterization and help to narrow down the differential diagnosis. It also helps distinguish testicular from extra-testicular masses and solid from cystic lesions with their various tissue signal intensity and flow voids. MRI can also be used to provide additional information especially if the ultrasound technique is equivocal or inconclusive.<sup>8</sup> MRI, therefore, helps to resolve diagnostic dilemma due to its multisequence, multiaxial capabilities as well as excellent soft tissue resolution. Thus it has specific advantage of separating lipomatous from non-lipomatous tumours using the STIR (fat suppressed) sequence. The intensity of the two medially located scrotal masses were suppressed and became hypointense compared to the normal laterally placed testes that remained hyperintense on the T2 weighted MRI sequence. (Figure 3) MRI has also been found to be extremely useful in differentiating between benign and malignant lesions in scrotal and testicular pathologies. In a study done by Cramer et al,<sup>9</sup> in their study of the role of MRI in the differential diagnosis of scrotal and testicular disease in Germany, MRI was said to have demonstrated alterations in morphological characteristics like testicular septations, that allowed them distinguish various pathologic entities. Of specific significance in this particular study done by Cramer et al, out of 54 cases of malignant disease diagnosed on MRI, there were no false positives or false negatives diagnosis made on the basis of MRI and even majority of the histologic tumor type made on MRI were correct.<sup>9</sup> This indicates the importance of MRI in diagnosis of scrotal masses as seen in our index study.

A similar case was reported by Ali N. et al<sup>10</sup> in India of a 20 year old male patient with left paratesticular mass, a primary scrotal lipoma, mimicking polyorchidism

(triorchidism). Similarities with this index case is the age of the patient.

A systematic review done by Patel et al<sup>4</sup> of Magnetic Resonance Imaging to differentiate the histology of testicular masses with pathologic confirmation, in John Hopkins Hospital in Maryland USA, with the result of their study, questioned the contexts where MRI should be considered as the ideal investigation among patients who are to undergo orchiectomy for a suspicious mass on ultrasound and suggested more research to be done on the subject. This case therefore presents a scenario where MRI can help narrow down the histology of the testicular mass seen in a patient.

The treatment of scrotal lipoma is surgical excision with the definitive diagnosis being histology. In this index case, having concluded that the masses were not testes with the aid of MRI, it was then safe to surgically remove the masses without fear of compromising the patient's future fertility. In this case therefore, an excision biopsy was done which revealed on histology (Fig 5a&b), the scrotal masses were indeed scrotal lipomas.

### Conclusion

In conclusion, we have reported a case of bilateral primary lipoma in a 21year old Nigerian whose diagnosis was made with the aid of radiological imaging modalities like ultrasound scan, and more importantly MRI, was managed with surgical excision the of mass with histology giving the confirmatory definitive diagnosis and no resultant post op complication.

### Conflict of Interest

There is no conflict of interest.

### Authors Contribution

All authors participated in the Concept and design of study or acquisition, analysis and interpretation of data, drafting and final review of the article.

### References

1. Kaplanoglu V, Kaplanoglu H, Parlak IS, Tatar IG. Giant intrascrotal lipoma. *BMJ Case Rep.* 2013;1- 2.
2. Zarami AB, Ibrahim H, Ibrahim AG, Ab Z, Ibrahim H, Ag I. Giant scrotal lipoma?: Case report and review of literature. 2019;(April):1-5.
3. Kim SO, Im CM, Joo JS, Oh KJ, Jung S Il, Park K, et al. Scrotal Primary Lipoma With Unusual Clinical Appearance in Newborn. *Urology.* 2009 May;73(5):1024-5.
4. Patel HD, Ramos M, Gupta M, Cheaib JG, Sharma R, Zhang A, et al. Magnetic Resonance Imaging to Differentiate the Histology of Testicular Masses: A Systematic Review of Studies With Pathologic Confirmation. *Urology [Internet].* 2020;135:4-10. Available from : <https://doi.org/10.1016/j.urology.2019.09.025>
5. Seidu AS, Yorke J, Akpaloo J, Danso P, Sukenibe SS, Fiifi-Yankson PK, et al. Giant primary scrotal lipoma in a low-resource setting: challenges with diagnosis and review of literature. *J Surg Case Reports.* 2021;2021(9):1-3.
6. Seidu AS, Yorke J, Akpaloo J, Danso P, Sukenibe SS, Fiifi-Yankson PK, et al. Giant primary scrotal lipoma in a low-resource setting: challenges with diagnosis and review of literature. *J Surg Case Reports.* 2021 Sep 1;2021(9).
7. Nouioui MA, Taktak T, Mokadem S, Gargouri F, Mediouni H, Khiari R, et al. A Paratesticular Angiolipoma: A Case Report of a Rare Benign Scrotal Mass and Review of Literature. *Case Rep Urol.* 2019;2019(Figure 3):1-3.
8. Akbar SA, Sayyed TA, Jafri SZH, Hasteh F, Neill JSA. Multimodality Imaging of Paratesticular Neoplasms and Their Rare Mimics. *Radiographics.* 2003;23(6):1461-76.
9. Cramer BM, Schlegel EA, Thueroff JW. MR imaging in the differential diagnosis of scrotal and testicular disease. *Radiographics.* 1991;11(1):9-21.
10. Ali N, Kumar Singh KA. Left paratesticular mass mimicking polyorchidism: A case report. *Indian J Case Reports.* 2024 Jan 31;9(5):122-4.
11. Bergholz R, Wenke K. Polyorchidism: A Meta-Analysis. *J Urol.* 2009 Nov;182(5):2422-7.